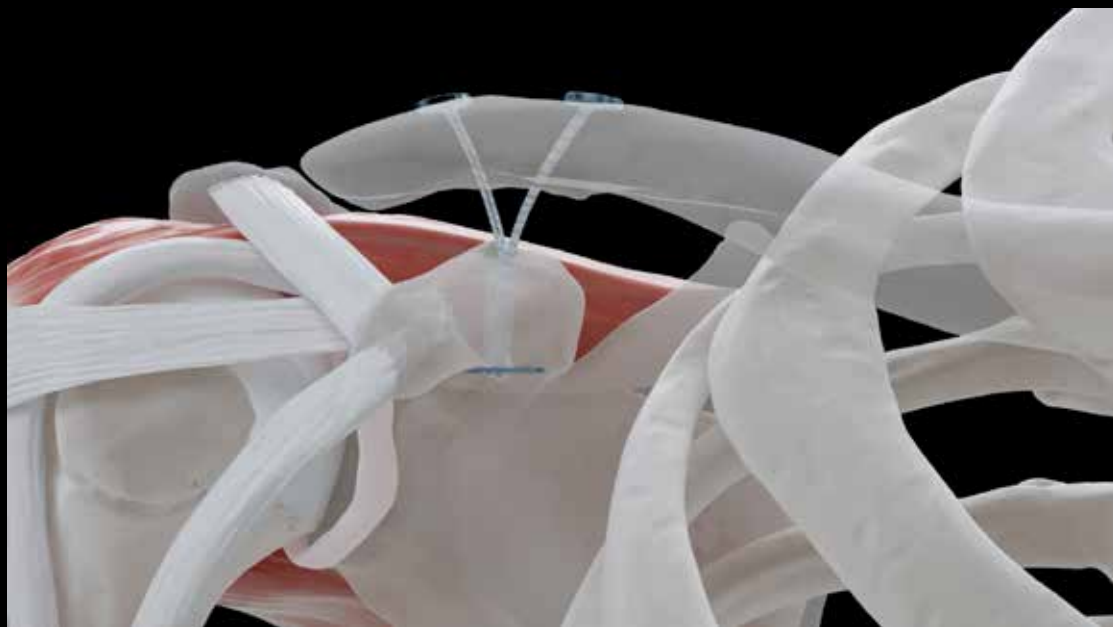
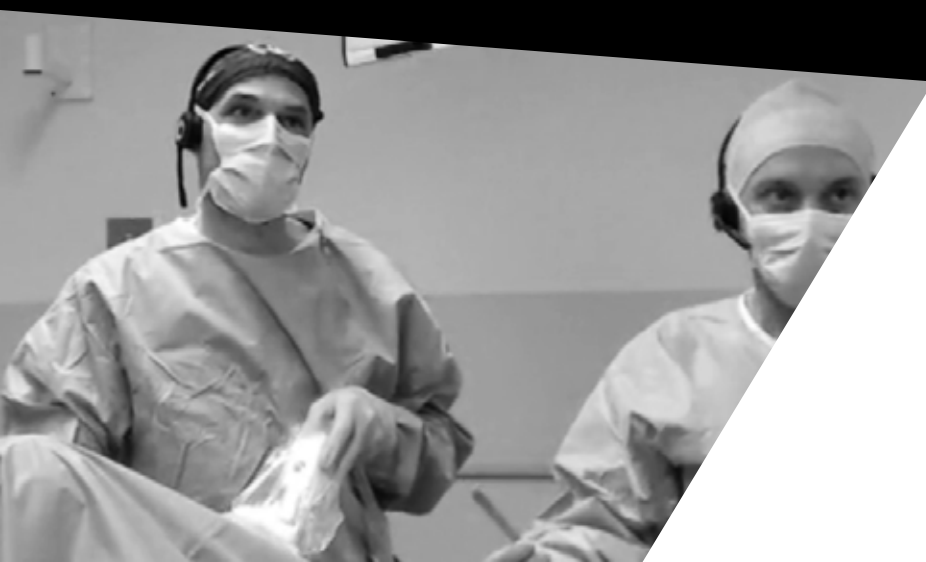
OPERATING TECHNIQUE



# Acromioclavicular Ligamentoplasty

WITH ADJUSTABLE FIXATION SYSTEM

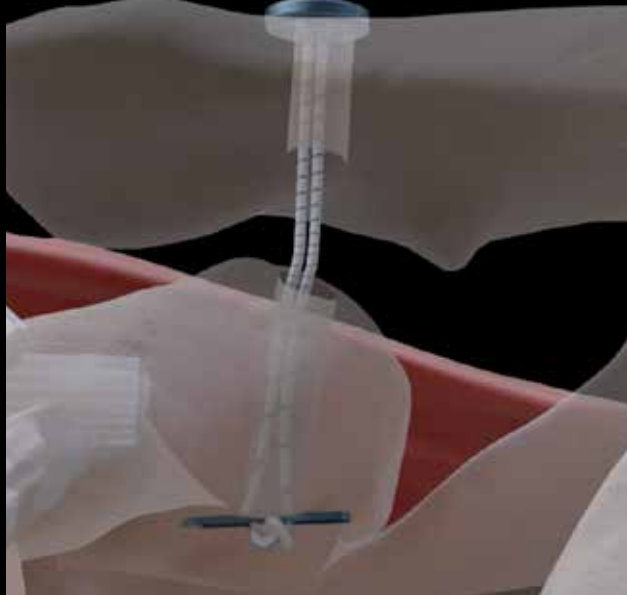

**VIMS**  
a Zimmer Biomet Company

## Introduction

The Button Loop fastening system restores the anatomy of the shoulder and especially the acromioclavicular joint in the event of acute, chronic disjunction or even fracture of the distal fourth of the clavicle. The technique is minimally invasive (possible under arthroscopic assistance, with small diameter tunnels) and simplified to make it accessible to all. Its variable length double ligament and self-locking system adapts to all morphologies of the shoulder and allows a simple assembly (direct coraco-clavicular) or «V», much more anatomical.

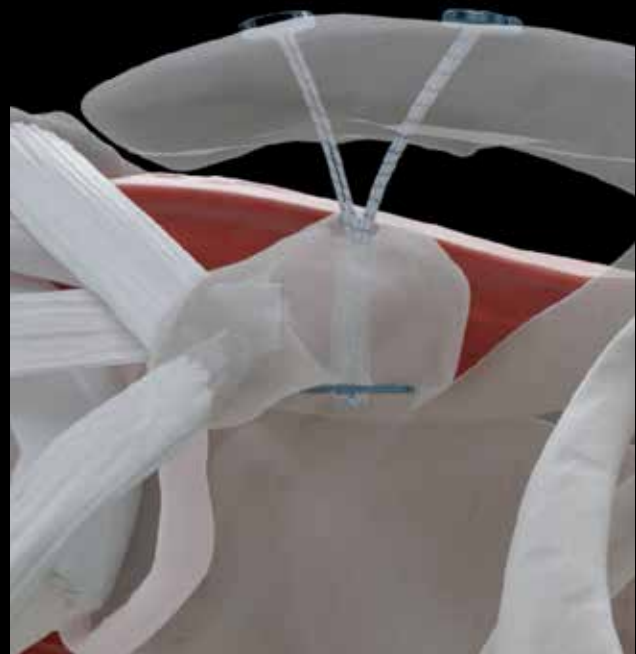It makes it possible to reconstruct a physiological isometry, a fundamental principle of the control of vertical and horizontal displacement.



## Indication

The Button Loop is indicated in case of acute or chronic acromioclavicular dislocation of type 3 of the Rockwood classification (total rupture of the 3 ligaments: trapezoid, conoid and acromioclavicular), types 4 (same but with interposition of the delto-trapezial clevis making percutaneous reduction impossible) and in case of fracture of the external 1/4 of the clavicle.

In case of injury less than 10 days old, the Button Loop alone will suffice. In case of lesion beyond 10 days, a «Weaver and Dunn» type supplement (coracoacromial ligament graft on the distal part of the clavicle) will be essential.

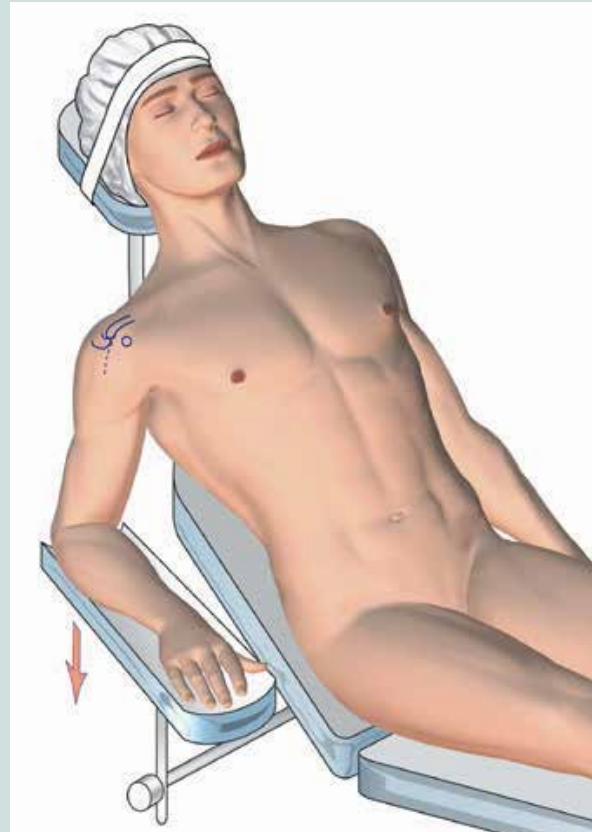


## Main steps

1. Preparation of vertical tunnels through clavicle
2. Opening of the rotator interval and preparation of the coracoid process.
3. Locating tunnels on the underside of the clavicle
4. Locating the acromioclavicular joint
5. Setting up the Button Loop

## Installation

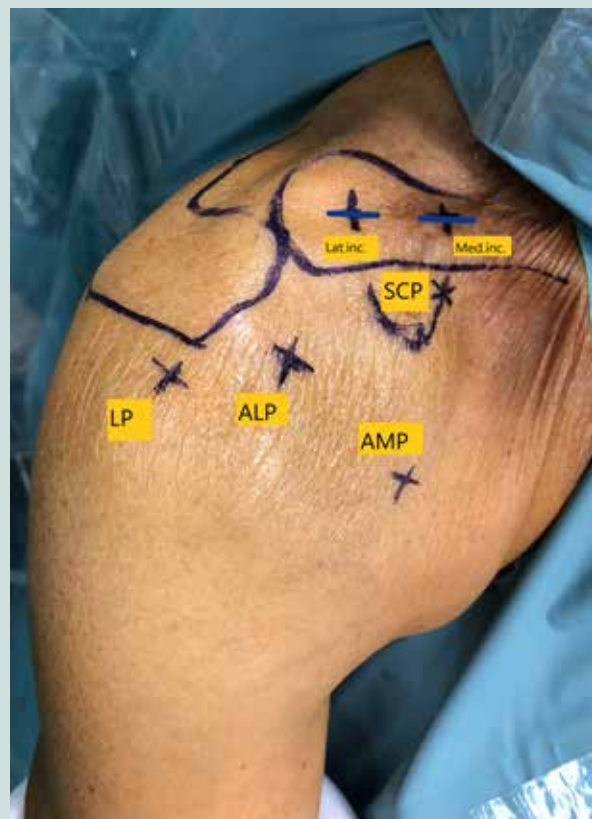
The patient will be in the beach chair position with complementary locoregional anesthesia. The arm is kept free to allow reduction at the end of the intervention, while tensioning the Button Loop; also it's positioned on a pneumatic arm with a slight forward flexion and internal rotation to increase the volume of the future working chamber in front of the coracoid process.



## Voies d'abord

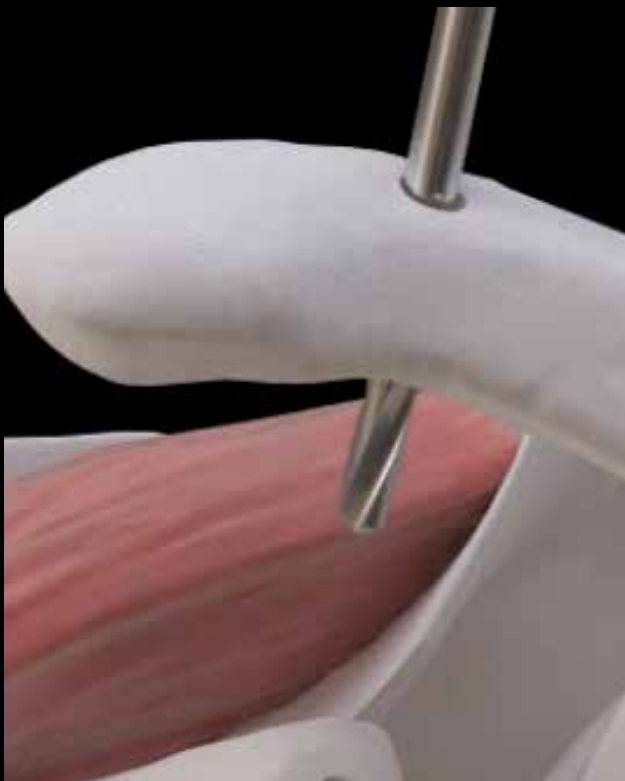2 superior surgical approaches: **LATinc** and **Medinc** separated by 2 cm, are made over the clavicle to perform 2 vertical tunnels. These incisions will be approximately of 1 cm to allow the implantation of the 2 Button Loop fixing buttons. The most lateral tunnel will be located 2 cm from the acromioclavicular junction.

It will also require a posterior **P** (soft point) portal to visualize the glenohumeral joint, an anterosuperior **AS** portal to open the rotator interval (respecting the coraco- acromial ligament that can be used as a transplant in case of Weaver and Dunn), an antero-medial (**AMP**) portal for subclavicular dissection, an anterolateral portal (**ALP**) for Button Loop passage, and finally an upper **SCP** portal for the vertical tunnel through the coracoid process.



## 1- Preparation of vertical tunnels through the clavicle

This is the first stage of the operation, before any arthroscopic procedure: this allows to be more precise before the inevitable secondary swelling of the shoulder due to the arthropump. A specific guide and a 2.4 mm drill bit allows to make the two parallel, vertical and convergent tunnels, towards the coracoid process. The lateral tunnel should be positioned as close as possible to the anterior edge while the medial tunnel should be close to the posterior edge. This is by far the most difficult gesture of this operation, the most common mistake being the realization of a tunnel too anterior with a risk of fracture of the clavicle if it is unicortical. The passage of the two cortices (upper and lower) of the diaphysis of the clavicle should be carefully verified. Special care should be taken when perforating the medial tunnel to avoid vascular or neurological damage close to the under face of the clavicle. A loop will then be introduced in each tunnel, and serve as a benchmark for arthroscopic time.



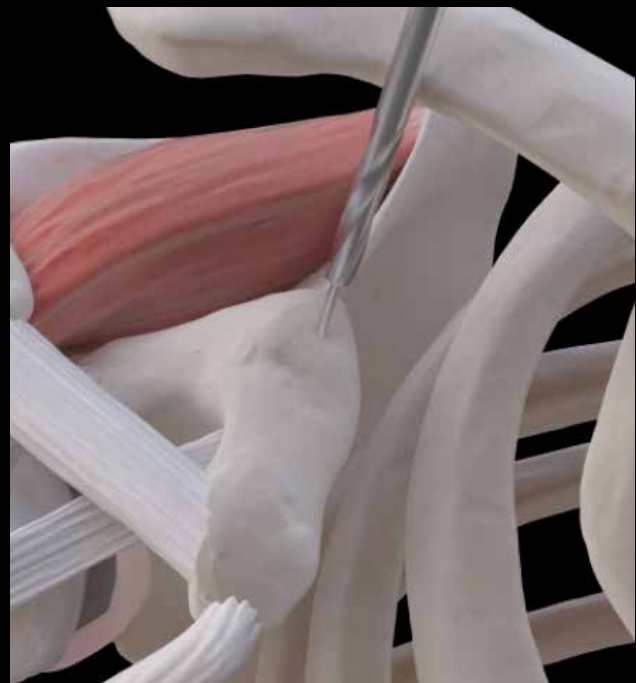
## 2- Opening of the rotator interval and preparation of the coracoid process

The arthroscope will be placed in the soft point to explore the articulation. Then through the AS portal, the whole rotator intervals removed using the coblation. This will control and repair an eventually associated SLAP lesion, a labral lesion or a rotator cuff lesion. In our experience, this eventuality has remained rather rare. The coracoid process and the conjoint tendon should be completely dissected, while respecting the coracoacromial ligament, which will be detached from the acromion and mounted on wires in case of an associated Weaver Dunn procedure with the aim of reinserting it to the underside of the clavicle, at the lateral tunnel, reinforcing the lateral arm of the «V Of the Button Loop.

The arthroscope will then be placed in the AS portal and the coblator in the AM portal to continue the dissection at the superior surface of the coracoid process and under the inferior surface of the clavicle. A third tunnel of 2.4 mm, vertical, will be realized through the coracoid process, to allow passage of the Button Loop.

Again, it will be necessary to be very precise, by using a special guide to avoid any secondary fracture, by drilling from top to bottom and from inside to outside, consistent with biomechanical studies .

If you want to use two endo buttons to increase the stability of the reduction, you should do a tunnel of 3.2 through the base of the coracoid process.



### 3- Tunnel Tracking on the underside of the clavicle

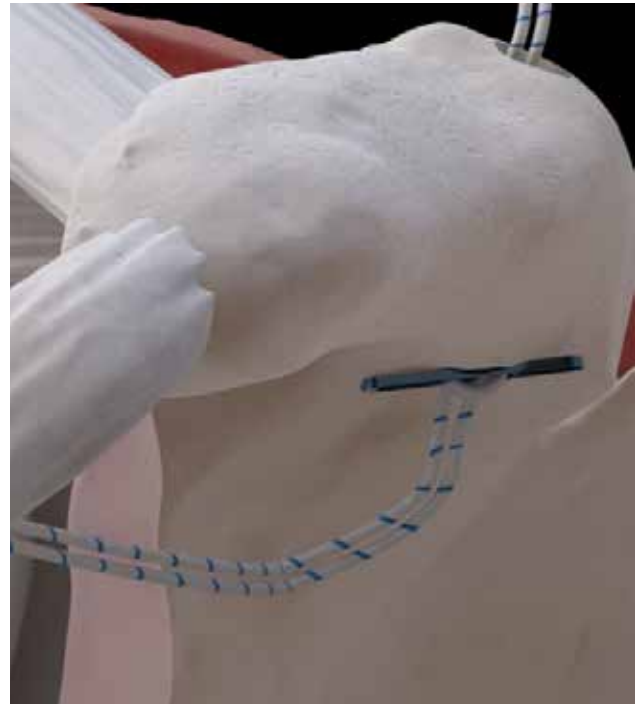
The dissection will then proceed to the underside of the clavicle to identify the 2 tunnels with their respective loops. The control of the medial tunnel can be dangerous because of the proximity of the sub clavian pedicle.

### 4- Locating the acromioclavicular joint

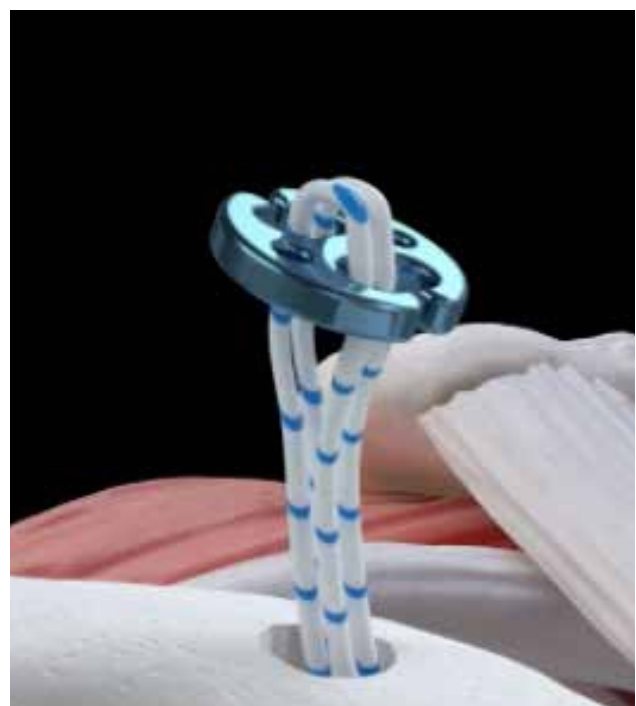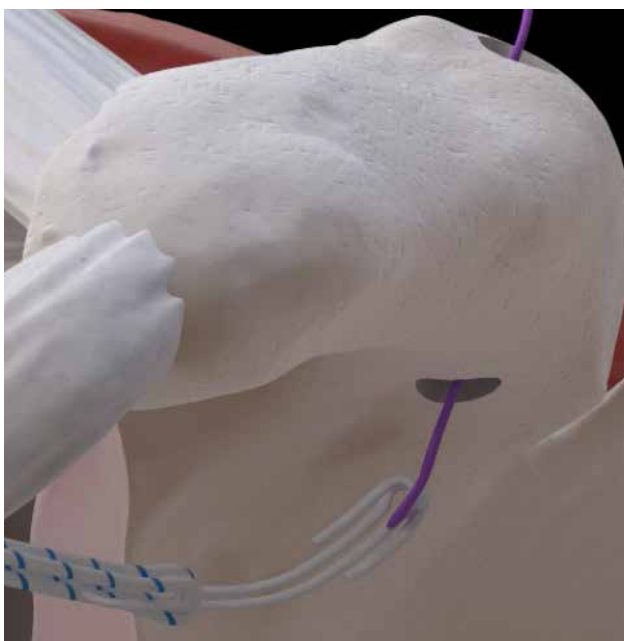
The acromioclavicular junction should then be checked to ensure that no soft tissues are interposed, particularly in Rockwood types 4, and to achieve adequate release if necessary. We have abandoned the systematic resection of the intra-articular meniscus to avoid osteoarthritic decompensation of this joint. It is fundamental to test both the vertical and horizontal reducibility of the joint by provisionally releasing the pneumatic articulated arm.

### 5- Positioning of the Button Loop

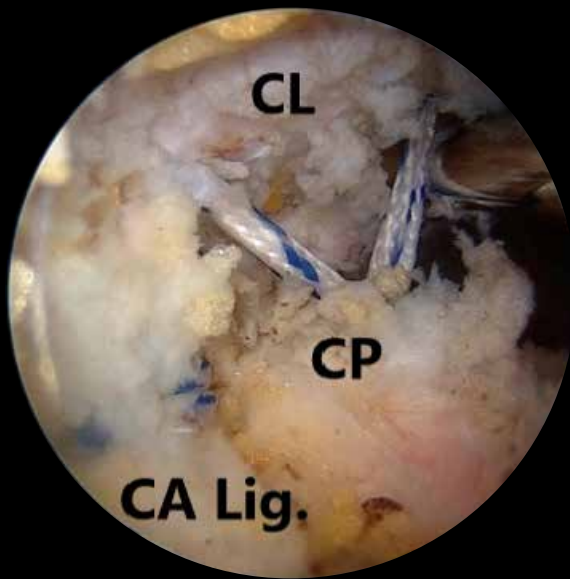The button loop should be introduced through the tunnel of the coracoid process with a PDS shuttle relay. Each strand of the button loop are retrieved through each clavicular tunnel to reproduce the « V » direction of the two coraco clavicular ligaments. To simplify the procedure, it is possible to perform only one tunnel through the clavicle and the two strands of the button loop are retrieved through this tunnel: This second technique is not isometric and doesn't reduce perfectly the vertical and horizontal displacement. To increase the resistance of the reduction, it is possible to use two button loops with the same technique but with a bigger tunnel through the clavicle (3.2mm).



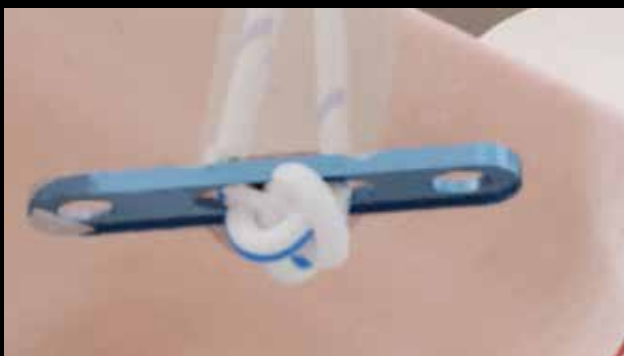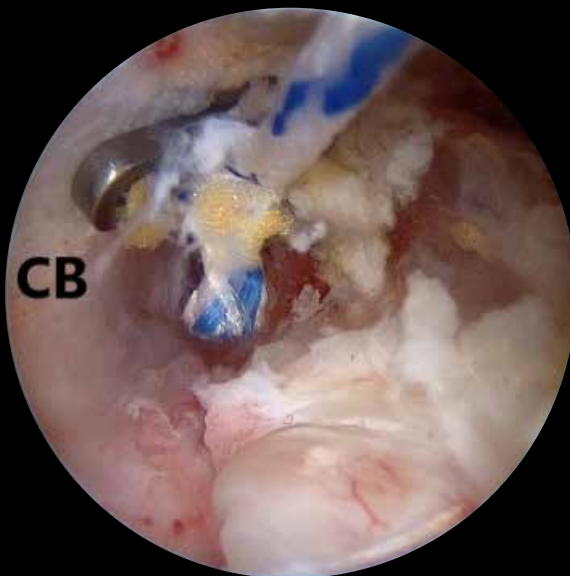
Then, two open buttons are positioned over the clavicle through the two button loop. While tensioning the button loop, the pneumatic arm is released and we combine a down pressure of the clavicle and a pulling of the upper limb. The reduction of the dislocation is controlled by an arthroscope view through the AL portal and we confirm that the acromion clavicular ligament is not inside the joint but perfectly reduced. A control scopic can be done with an antero posterior view and an axillary view to check the reduction the vertical and horizontal displacement. This progressive lock system allows a progressive and optimum reduction and fixation.





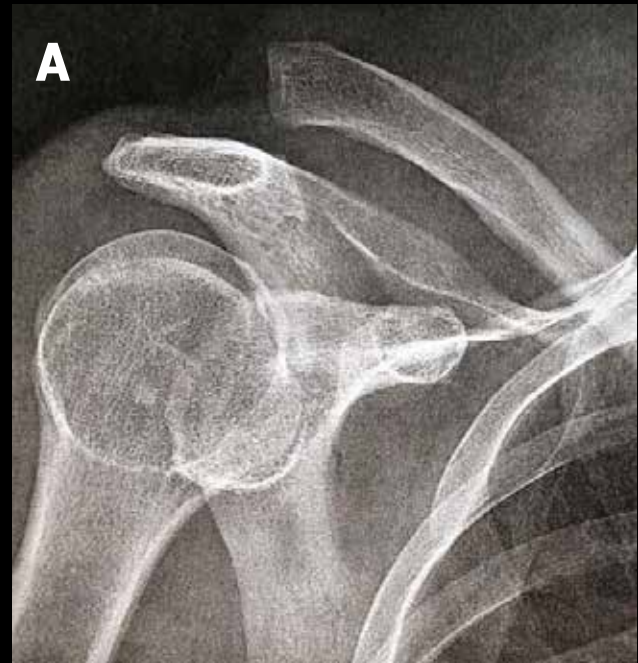

It will be enough to finish the gesture by a safety knot which will asymptomatic, being located at the level of the knee of the coracoid apophysis.

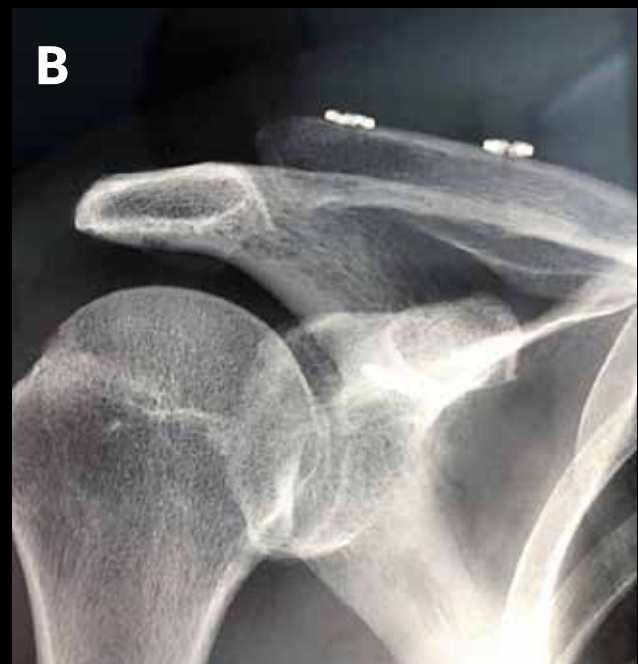

## Postoperative Follow-up

A Dujarrier will be installed for 4 weeks. Pendulum exercises will begin immediately. Active range of motion will be started at the end of the first month. At 3 months, and in case of acute injury, the patient can resume all his sports activities, including contact sports. In the case of associated Weaver and Dunn procedure, contact sports can only be resumed after 9 months.



A : preoperative radiography



B : post-operative

## Chronical cases

After the 10th day, it is best to combine a coracoacromial ligament graft with the previous setup. The idea is to combine the simple tunnel technique described above (located 4 cm from the acromioclavicular joint) with a second, more lateral tunnel (located 2 cm from the acromioclavicular joint) in which the coracoacromial ligament graft will be fixed and pedicled on the lateral edge of the coracoid process. A looped return around the acromion will also be associated with this to achieve horizontal acromioclavicular stabilisation.

To do this, a «triple Krakow» type suture must be used with a non-absorbable thread (ref). We use a particularly simple «shuttle relay» type loop technique. It is important to free both the superficial (sub deltoid) and deep face of this ligament, up to its insertion on the acromion, which often extends to its lower face. The optic will be introduced into the superior-lateral approach in order to control these two surfaces. The acromial insertion of the coracoacromial ligament is then detached; we have abandoned the idea of removing an associated bone rod, as it is not very useful and even troublesome for reinserting the graft on the lower surface of the lateral tunnel of the clavicle. This suture will be introduced into the lateral tunnel and fixed by a second endobutton to the upper surface of the clavicle.

A third endobutton mounted on a final suture is used: this is also inserted into the lateral tunnel from the underside of the clavicle. The endobutton will thus be «blocked» on the underside of the tunnel in a very solid manner and it will then be possible to make a loop around the acromion by a path that is both subcutaneous and subacromial.

## References

### **Wolf EM, Pennington WT**

Arthroscopic reconstruction for acromioclavicular joint dislocation. *Arthroscopy* 2001; 17:558–563

### **Boileau P, Old J, Gastaud O, Brassart N, Roussanne Y.**

All-arthroscopic Weaver-Dunn-Chuinard procedure with double-button fixation for chronic acromioclavicular joint dislocation. *Arthroscopy*. 2010 Feb;26(2):149–160.

### **Lafosse L et al**

Arthroscopic treatment of acute and chronic acromioclavicular joint dislocation *Arthroscopy*. 2005 Aug ;21(8): 1017.

### **Jean Kany, Hisham Anis.**

Arthroscopic reconstruction of coracoclavicular ligaments with CA ligament augmented with suspensory “V shape” fixation system for chronic acromioclavicular joint dislocation. *Technics in Arthroscopy* (in press) 2019

### **Barth J, Duparc F, Baverel L, Bahurel J, Toussaint B, Bertiaux S, et al.**

Prognostic factors to succeed in surgical treatment of chronic acromioclavicular dislocations. *Orthop Traumatol Surg Res*. 2015 Dec 1;101(8):S305–S311. doi:10.1016/j.otsr.2015.09.002

### **Clavert P, Meyer A, Boyer P, Gastaud O, Barth J, Duparc F, et al.**

Complication rates and types of failure after arthroscopic acute acromioclavicular dislocation fixation. Prospective multicenter study of 116 cases. *Orthop Traumatol Surg Res*. 2015 Dec 1;101(8):S313–S316. doi:10.1016/j.otsr.2015.09.012

### **Shin SJ, Kim NK.**

Complications after arthroscopic coracoclavicular reconstruction using a single adjustable-loop-length suspensory fixation device in acute acromioclavicular joint dislocation. *Arthroscopy*. 2015 May;31(5):816–24. doi: 10.1016/j.arthro.2014.11.013. Epub 2014 Dec 25. PMID: 25543250

### **Thangaraju S, Tauber M, Habermeyer P, Martetschläger F.**

Clavicle and coracoid process periprosthetic fractures as late post-operative complications in arthroscopically assisted acromioclavicular joint stabilization. *Knee Surg Sports Traumatol Arthrosc*. 2019 Mar 21. doi: 10.1007/s00167-019-05482-7. [Epub ahead of print] PMID: 30900030

### **Barth J, Duparc F, Andrieu K, Duport M, Toussaint B, Bertiaux S, et al.**

Is coracoclavicular stabilisation alone sufficient for the endoscopic treatment of severe acromioclavicular joint dislocation (Rockwood types III, IV, and V)? *Orthop Traumatol Surg Res*. 2015 Dec 1;101(8):S297–S303. doi:10.1016/j.otsr.2015.09.003

### **Kany J, Guinand R, Croutzet P.**

All arthroscopic augmented Vargas procedure: An option after failed acromioclavicular joint dislocation reconstruction. A technical note. *Orthop Traumatol Surg Res*. 2016 Sep 1;102(5):669–672. doi:10.1016/j.otsr.2015.12.022

### **Hann C, Kraus N, Minkus M, Maziak N, Scheibel M.**

Combined arthroscopically assisted coraco- and acromioclavicular stabilization of acute high-grade acromioclavicular joint separations. *Knee Surg Sports Traumatol Arthrosc*. 2018 Jan;26(1):212–220. doi: 10.1007/s00167-017-4643-2. Epub 2017 Jul 17. PMID: 28717889

### **Tauber M, Valler D, Lichtenberg S, Magosch P, Moroder P, Habermeyer P.**

Arthroscopic Stabilization of Chronic Acromioclavicular Joint Dislocations: Triple- Versus Single-Bundle Reconstruction. *Am J Sports Med*. 2016 Feb;44(2):482–9. doi: 10.1177/0363546515615583. Epub 2015 Dec 9. PMID: 26657259

## Instrumentation

DESCRIPTION	REFERENCE
Guide	0902-0142
Shutter	0902-0144
Cannulated forest 2,4mm L 265mm	0902-0141
Cannulated forest 3,2mm L 265mm	0902-0151
Pince tape cutter	231220FRV



## Implants

DESCRIPTION	SIZE / COLOR	REFERENCE
Adjustable Button Loop External	White / Blue	VSDL-2001
Adjustable Button Loop External	White / Green	VSDL-2002
Titanium Shoulder Button	8mm - Blue	VDL-2000B
Titanium Shoulder Button	8mm - Green	VDL-2000G
Titanium Shoulder Button	10mm - Blue	VDL-2010B
Titanium Shoulder Button	10mm - Green	VDL-2010G

## Storage

ARTHROVIMS BUTTON systems must be stored in their original undamaged packaging in a clean, dry environment at room temperature. For further information, please read the instructions for use.

## Products

BUTTON ARTHROVIMS are packed in double sterile packaging. They are sterilised with ethylene oxide according to ISO 11135 and are ready to use. Single use only. Do not reuse or re-sterilise.



1984

CLASSE IIB / ADJUSTABLE FASTENING SYSTEM  
OPEN BUTTON  
TITANIUM SUTURES



CLASSE I NON-STERILE / INSTRUMENTATION

Document creation date : March 2021 - Manufacturer : DORATEK - Range : Osteosynthesis, tendon and ligament anchoring system - Product name : ADJUSTABLE BUTTON LOOP, TITANIUM SHOULDER BUTTON - Addressee: Health professional - CE marking N°: 1984 - DM Class: IIB - Reimbursable by health insurance organisations in certain situations - Consult modalities on the ameli.fr website - Indications: fixation system accessory, textile prosthetic tendon implant - Recommendations for use: it is strongly advised to read the label and the instruction leaflet of the product. Copyright © 2018 VIMS SA.

LVIMS products and devices are protected by international patents. The information contained herein is subject to change without notice.

TO\_DAC\_EN\_V01



10 AVENUE DE FONTRÉAL - EUROCENTRE  
31620 VILLENEUVE LES BOULOC - FRANCE  
TÉL. +33 5 34 45 09 09 - FAX. +33 5 61 22 85 84  
VIMS-SYSTEM.COM

A ZIMMER BIOMET company