


**SURGICAL TECHNIQUE**



# Arthroscopic Bankart-Latarjet

Specific guides and dual compressive  
self-locking fixation system

**Dr. Philippe Valenti**



**VIMS**

## key surgical steps

1. Intra-articular preparation
2. Preparation of the coracoid
3. Split of the subscapularis
4. Coracoid drilling and flattening
5. Glenoid drilling
6. Transglenoid and transcoracoid passage of adjustable fastening systems
7. Coracoid Osteotomy
8. Coracoid descent and glenoid fixation
9. Bankart repair

## Patient positioning

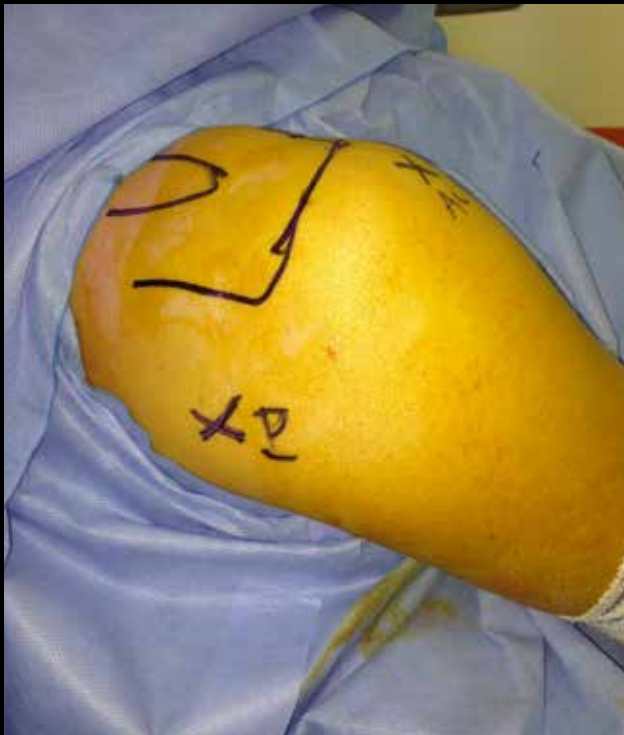The patient is placed in a beach-chair position with the arm in 30° of forward flexion, using a weak traction of 500g, neutral rotation, to easily mobilize the humeral head laterally and backwards. Also a bump is positioned along the medial border of the scapula to achieve scapular external rotation (decrease the risk of iatrogenic axillary nerve palsy).

Arthroscope: **P**-portal for steps **1)** and **9)**

Arthroscope: **AL** portal for steps **2) 3) 4) 5) 6) 7)** and **8)**

So 2 @ portals (**P** and **AL**) and 2 instrumental portals(**AI** and **S**)

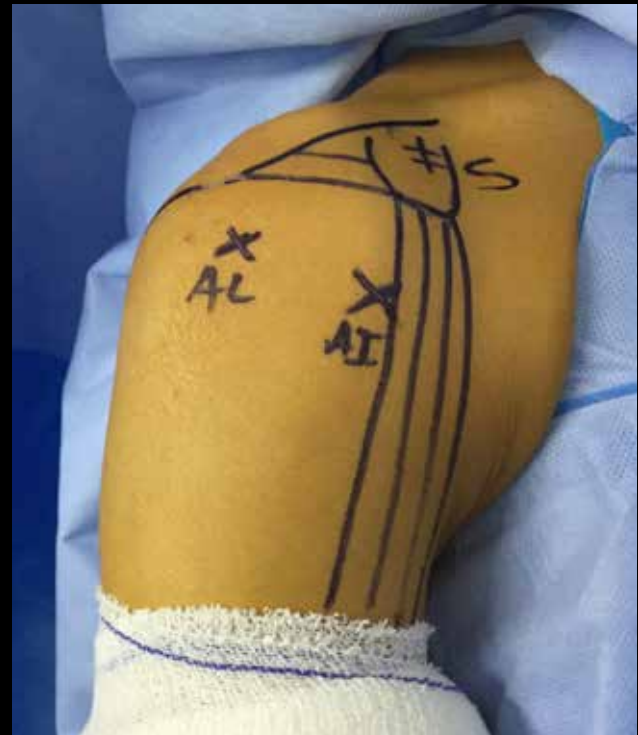All the portals are created under arthroscopic control from the posterior portal viewing.



**P**

**Posterior**

Lower than the soft point, aligned of the articular surface of the glenoid.  
Between 6h and 9h



**AL**

**Anterolateral**

3cm distal to the antero-lateral border of the acromion.  
at the level of the inferior border of the coracoid process.  
Intra articular viewing portal, and visualizes the anterior side subscapularis

**AI**

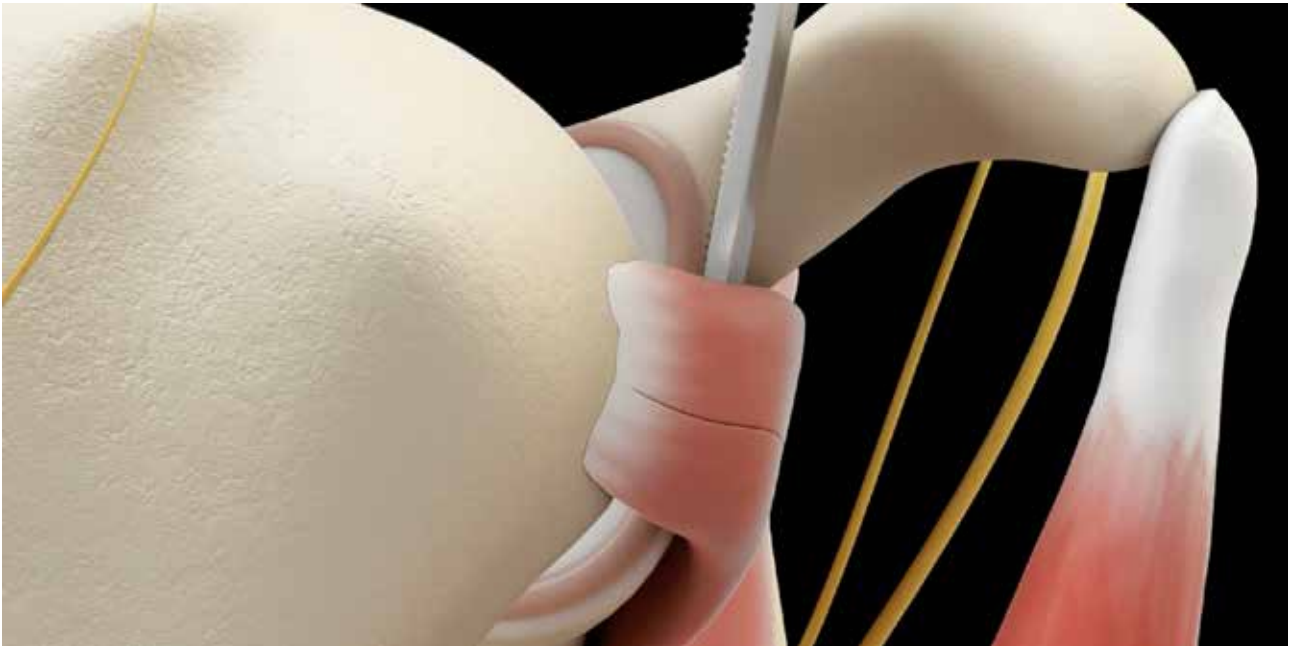
**Anteroinferior**

2 cm distal to the tip of the coracoid process, lateral the the conjoint tendon.  
Visualizes the coracoid process, the subscapular split, the musculocutaneous and the axillary nerves.

**S**

**Superior (coracoide)**

At the medial edge of the coracoid (because the coracoid is helical and inclined in 2D) for coracoid preparation and drill-guide insertion.



### 1° Intra articular preparation

**P portal (@) / AI Portal (instruments)**  
**AL portal (instruments)**

- Through **P** portal @ inspection of lesions
- **AI** portal, resection of the rotator interval; detachment of the labrum and the anterior capsule from 3 to 6 o'clock until the muscular fibers of the subscapularis are visualized. 2 capsulolabral wires are passed and then retrieved through the **AL** portal. Future bankart repair will be achieved at the end of the procedure.
- The future position of the bone block is marked using the VAPR.
- Debridement and flattening of the antero-inferior edge of the glenoid using a manual or a motorized rasp.

### 2° Coracoid preparation

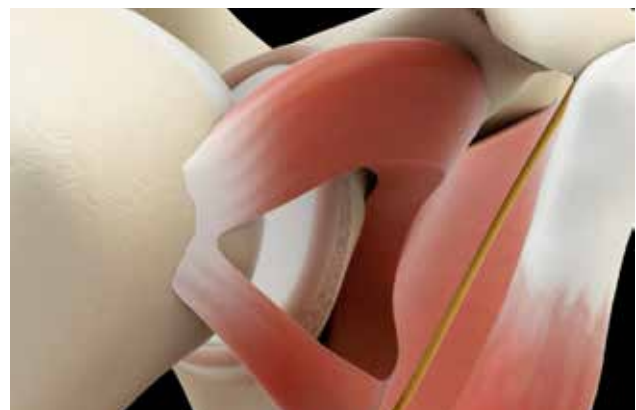**AI portal @ / S Portal (instrumental)**  
**AI portal (instrumental)**

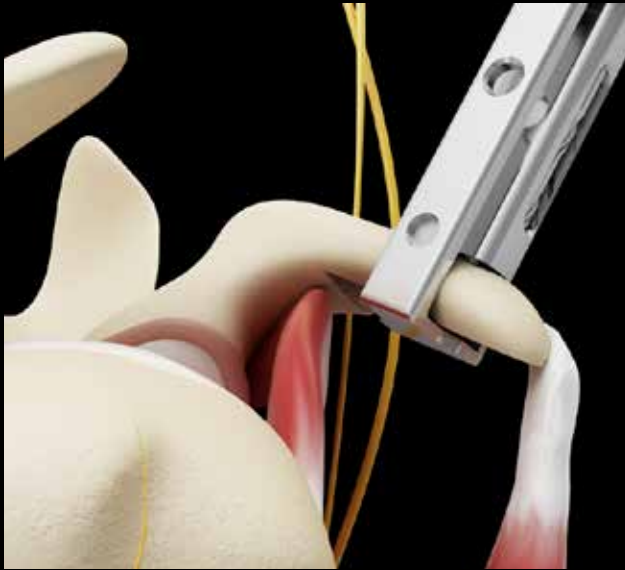- A blunt trocar is inserted through **AI** portal and used as a retractor to lift the deltoide muscle. A VAPR is introduced in the S portal (medial edge of the coracoid) to finish the preparation of the coracoid process.
- Cleaning the lateral and lower sides of the coracoid process.
- detachment of the coraco-acromial ligament
- detachment of the pectoralis minor from the medial border of the coracoid, without dissecting the brachial plexus
- Release distally 2 cm on the upper 1 cm on the medial part of the conjoint (pay attention to the axillary, musculo-cutaneous nerves, coraco-brachial vessels)

### 3° Subscapularis split

**P portal (@) / AI portal (instrumental)**

- Through **AL @** and **AI** Instrumental - A Wissinger rod inserted in the P portal and passed through the subscapularis muscle from posterior to anterior at the level of the future bone block, and remaining lateral to the conjoint tendon +++. The split of the subscapularis is now made from anterior to posterior using a VAPR (through **AI** portal) under **@AL** control
- The axillary nerve is bluntly dissected and visualized anteromedially to the subscapularis
- using a VAPR, the split is extended from medial to lateral, in line with muscle fibers, until the insertion on lesser tuberosity is reached. (A fairly long split facilitates the spreading of the subscapularis).
- The split of the subscapularis is carefully extended medially using a blunt trocar introduced by AI path while applying external rotation and repropulsion to the arm to avoid injury of the axillary nerve.



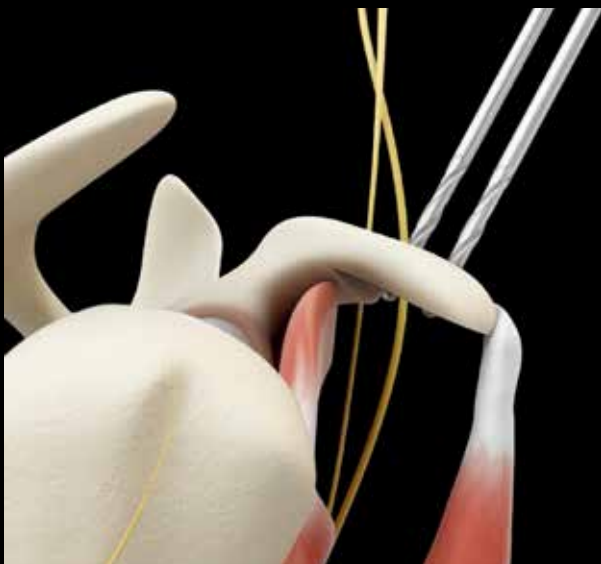


#### 4) Coracoid drillind

AL Portal (@ ) / S Protal (instrumental) and AI Portal (Instrumental)

Mark with 3 needles the anterior and posterior borders and the tip of the coracoid process

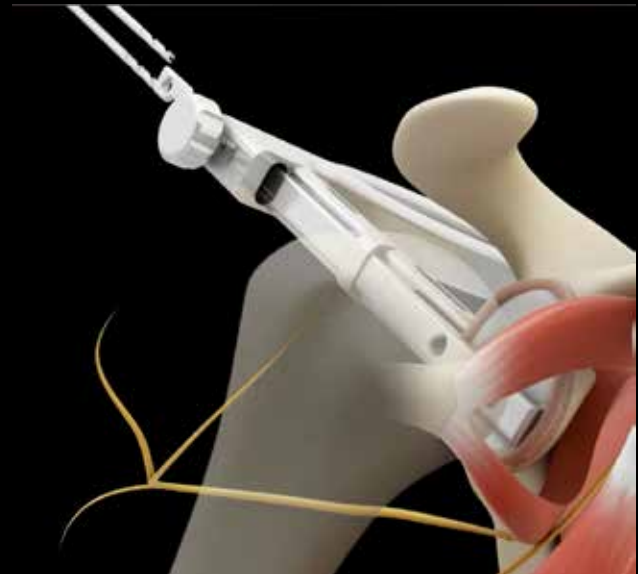- Position the guide on the upper side of the coracoid, then adapt the blade to the drill-guide to hook around the lateral edge of the coracoid process. Evaluate the orientation of the longitudinal axis of the guide in relation to its shape of the coracoid, with a slight 3D manipulation (attention the orientation of the coracoid which may be a little twisted and challenging for a good positioning of the guide).
- Drilling of the two transcoracoid tunnels from superior to inferior, 7mm medial to the lateral border, with a Ø3mm cannulated drill bit (2 different lengths)
- Leave both drill bits in place.
- Debridement and flattening of the lower edge of the coracoid using a flat cutter through **AI** portal (perpendicular to the holes).



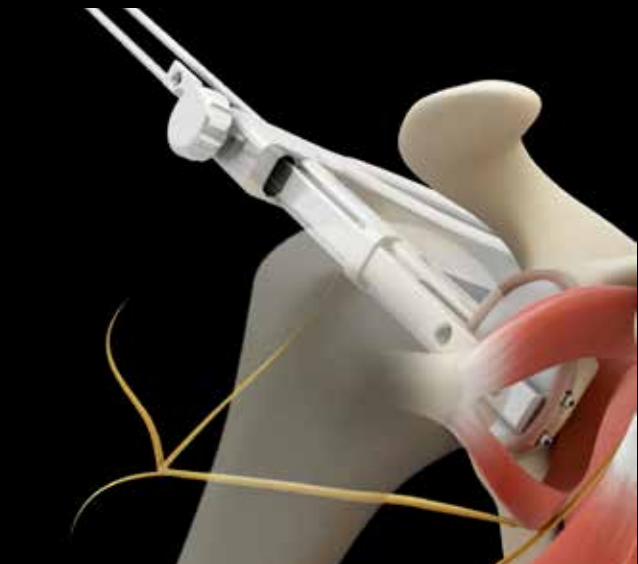#### 5) Glenoid drilling

AL Portal (@ ) / P Portal (instrumental)

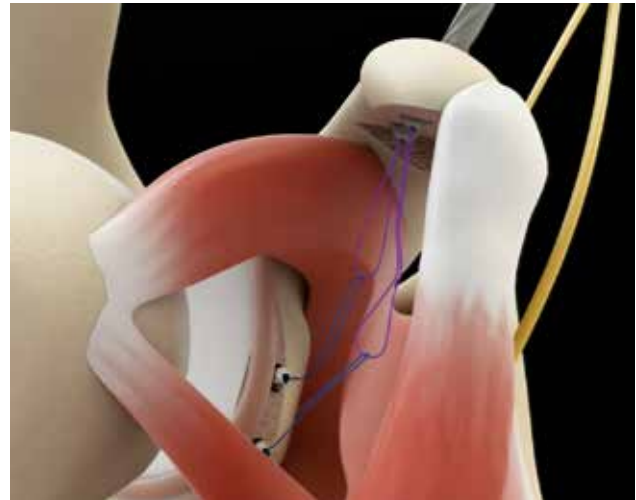
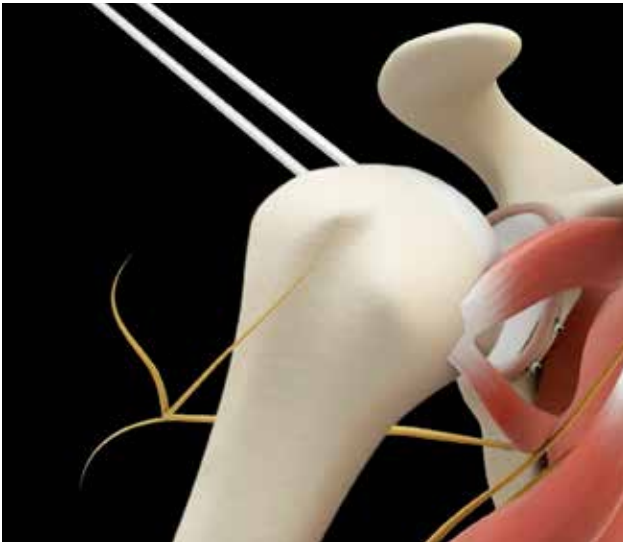
- Posterior capsulotomy between 6 and 9 hours, keeping the posterior labrum intact, which allows the insertion of the guide.
- Verification that the antero-inferior edge of the glenoid is well debrided and flattened.
- Position the guide in contact with the posterior edge of the glenoid between 6 and 9h then slide the blade to hook the anterior edge of the glenoid below the equator posterior path.



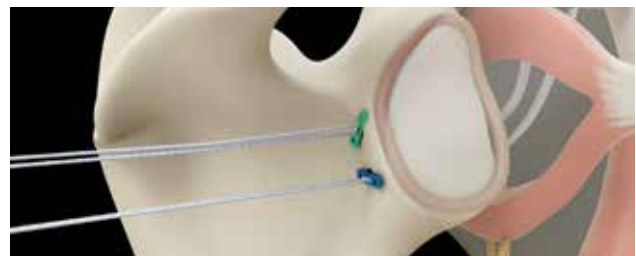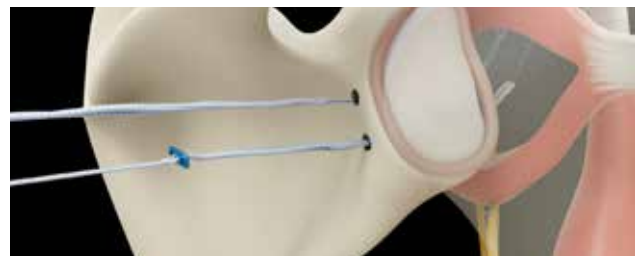- The guide is secured posteriorly by pushing the medial rod against the infra spinatus fossa and anteriorly with the help of a blunt trocar inserted in the AI portal. To be parallel to the glenoid articular surface, the previously mentioned trocar must apply pressure on the anterior depression located distally on the anterior side of the hook. Apply Scapular external rotation to medialize the axillary nerve position away from direction of the drill bits.



- Drilling of 2 transglenoid tunnels through the guide, 7 mm medial to the glenoid rim 3.0 cannulated drill bits. The length of the drilling is defined by the width of the glenoid indicated on the blade of the guide. The 2 drill bits (2 different lengths) exit at the level of the subscapularis split under arthroscopic control (AL) without passing through the subscapularis to prevent any iatrogenic axillary, or musculocutaneous nerve lesion.
- Remove the guide and leave both cannulated drill bits in place.



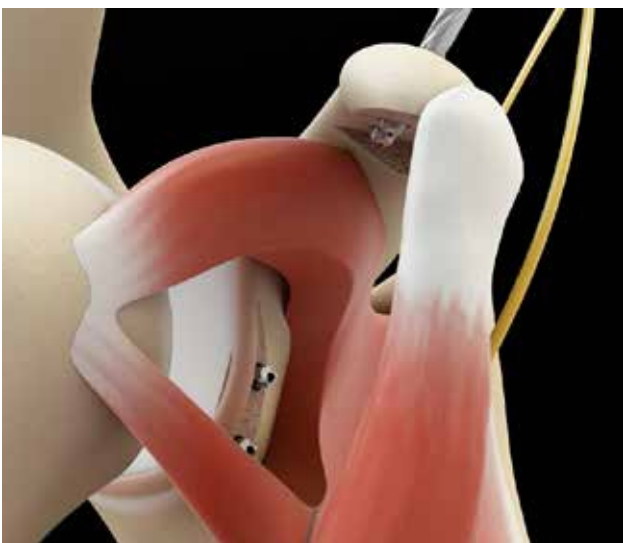
- Then the adjustable fixation implants from posterior to anterior which allows to retract the upper part subscapularis and thus facilitate the maintenance of the opening of the SSC split; then the same maneuver is repeated for the inferior glenoid and distal coracoid wires.



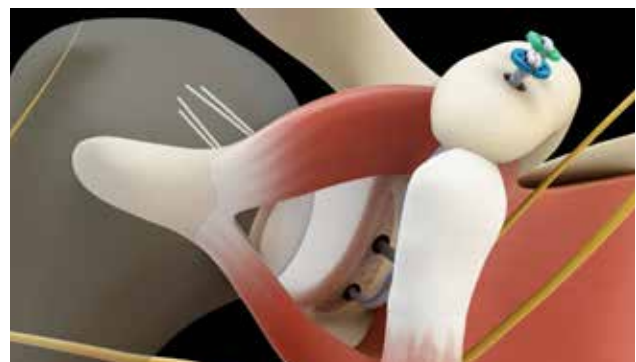
## 6) Implant positioning

### AL portal (@) / AI ,P, S Portals (instrumental)

- The split of the subscapularis is kept open by a «spreading clamp» (introduced by P portal) or by the use of 2 trocars (posterior and anterior) lifting the upper part upper and lowering the lower part of the subscapularis (2 different techniques)



- Positioning of the open coracoid cortical buttons: pass both wires of the loup in the open cortical button. Pull alternately and gently on the strands exiting through the posterior aspect of the glenoid until the cortical button is lowered and secured on the superior aspect of the coracoid process.

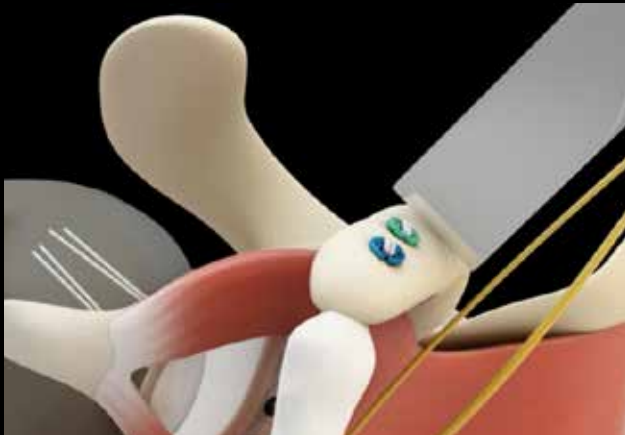


- The superior glenoid and proximal coracoid relay wires are first passed.

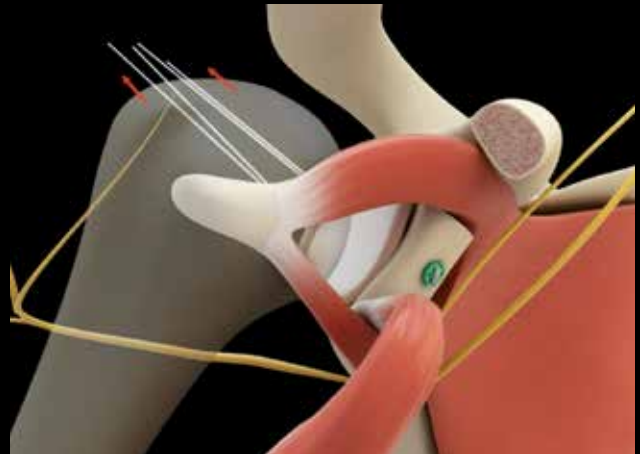
## 7) Coracoid osteotomy

AL Portal (@) / AI, S portal instrumental

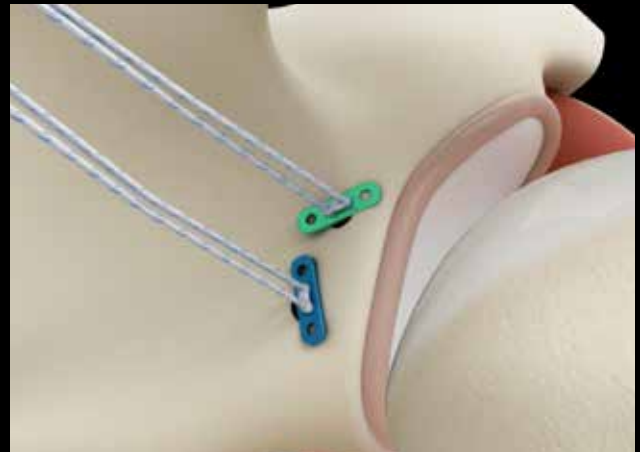- Check that the undersurface is flat (straight osteotome if needed)
- Using a curved osteotome, osteotomy of the coracoid distally to the conoid and trapezoid ligaments origin. Hold this coracoid with a specific forceps to facilitate the passage through the split of the subscapularis and its positioning at the antero-inferior part of the glenoid.



- Pull on the upper and lower strands alternately to facilitate the passage of the coracoid through the split subscapularis and then tighten the inferior strands
- The subscapularis split is maintained open using the subscapularis spreader or the posterior Wissinger pushing upwards and anterior trocar pushing down.
- Once intra-articular, position the coracoid in a vertical position below the equatorial line of the glenoid.
- Tighten the 2 adjustable fastening implants under arthroscopic control (AL) to apply the coracoid graft on the antero-inferior glenoid wall.



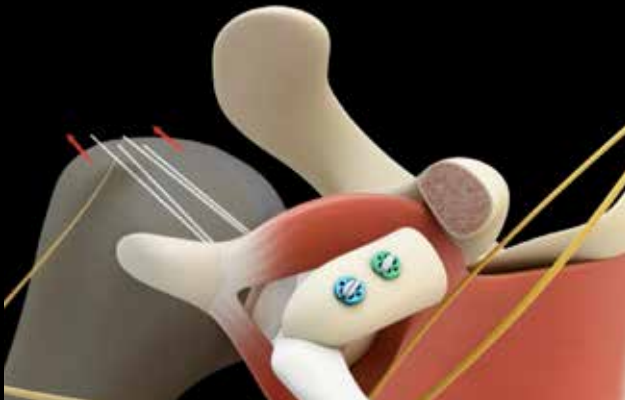
- Check, using a Wissinger rod inserted from the P portal, that the graft is flush with the joint.



## 8) Coracoid placement and fixation

AL portal (@) / AI portal (instrumental)

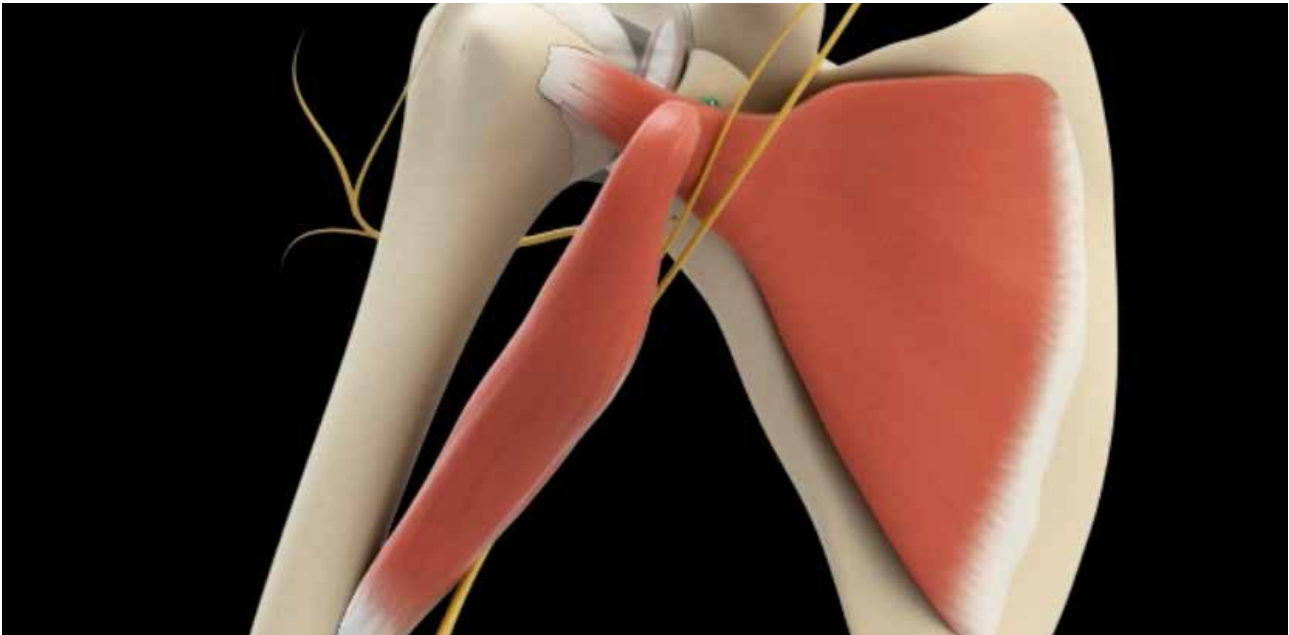
- Hold the coracoid bone block by a Museux-type forceps (AI) to direct it through the split of the subscapularis kept open by a subscapularis spreader.




- Make security knots posteriorly on the adjustable fixation implants.

## 9) Bankart repair

- Repair of the capsule and the inferior glenohumeral ligament using 3 anchors loaded antero-inferiorly on the glenoid edge just posterior to the posterior edge of the coracoid graft which becomes extra-articular.
- Closure of all portals.

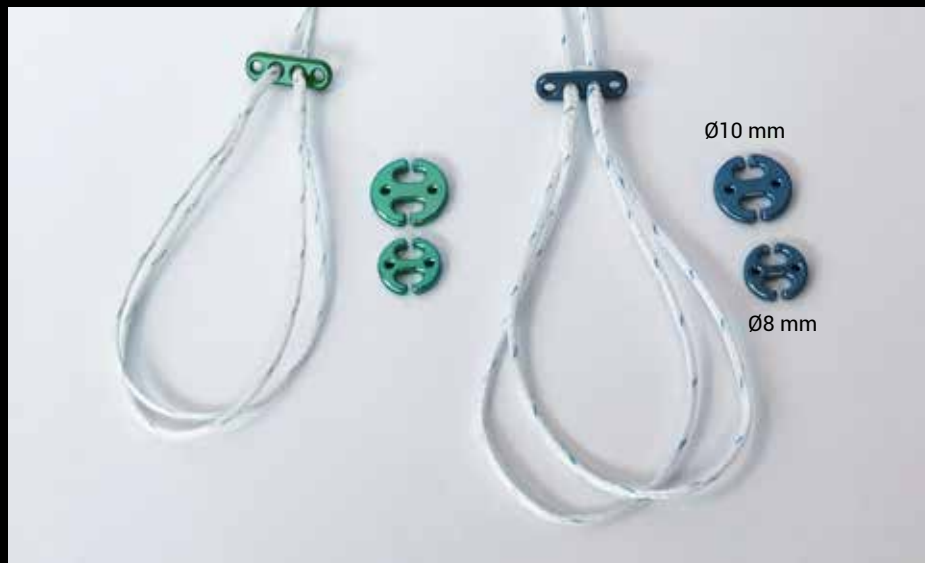

### Surgical instruments



	DESCRIPTION	REFERENCE	QUANTITY
	SPECIFIC GUIDE		
①	Guide body	0901-0110	1
②	Big Coracoid Hook	0902-0101	1
③	Small Glenoid Hook	0902-0102	1
④	Medial rod	0902-0103	1
⑤	Cannulated bit 240mm - Ø3 mm	0902-0131	2
⑥	Cannulated bit 200mm - Ø3 mm	0902-0132	2
	SUBSCAPULARIS SPREADER	0903-0110	1
	OSTEOTOME	452-102-11	1
	SUTURE TENSIONER	0903-0171	1
	GRASPER	BAS-9126	1
	CONTAINER	DIN_KIT_LATARJET	1

## Implants



DESCRIPTION	REFERENCE	QUANTITE
STANDARD LATARJET KIT	VLSK-06	
Adjustable fixation implant (external) white / blue	VSDL-2001	1
Adjustable fixation implant (external) white / green	VSDL-2002	1
Open button titanium 8 mm blue	VDL-2000B	1
Open button titanium 8 mm green	VDL-2000G	1
Suture UHMWPE white / blue	VHF-941	1
Suture UHMWPE white / green	VHF-942	1
SMALL LATARJET KIT SHOULDER	VLSS-03	
Adjustable fixation implant (external) white / blue	VSDL-2001	1
Open button Titanium 10 mm blue	VDL-2010B	1
Suture UHMWPE white / blue	VHF-941	1

### Storage

ARTHROVIMS BUTTON systems must be stored in their original packaging intact, in a clean and dry environment at room temperature. For any additional information, please read the instructions.

### Products

ARTHROVIMS BUTTON are packaged under double sterile packaging. They are sterilized with ethylene oxide according to ISO 11135 and are ready for use. Disposable. Do not reuse or resterilize.

CE 2292  
CLASSE IIB / SYSTÈME DE FIXATION RÉGLABLE  
BOUTON OUVERT TITANE  
SUTURES

CE  
CLASSE I NON-STÉRILE / INSTRUMENTATION

Date de création du document : Janvier 2021 - Fabricant : DORATEK - Gamme : Ostéo- synthèse, système d'ancrage tendineux et ligamentaire- Nom de Produit ARTHROVIMS ADJUSTABLE BUTTON LOOP, SUTURES, TITANIUM SHOULDER BUTTON - Destinataire : Professionnel de santé - N° de marquage CE : 2292 - Classe du DM : Iib - Remboursable par les organismes d'assurance maladie dans certaines situations - Consultez les modalités sur le site ameli.fr - Indications : Latarjet - Recommandations d'utilisation : il est fortement conseillé de lire l'étiquette et la notice d'instructions du produit.  
Fabricant : VIMS - Gamme : INSTRUMENTATION- Nom de Produit : Guide Latarjet- Destinataire : Professionnel de santé - CE - Classe du DM : I non stérile - Indications : Latarjet  
Copyright © 2018 VIMS SA.

Les produits et dispositifs VIMS sont protégés par des brevets internationaux. Les informations ci-contre sont sujettes à changement sans communication préalable.  
ST\_LATARJET\_BANKART\_EN\_V01



VIMS SA  
10 AVENUE DE FONTRÉAL - EUROCENTRE  
31620 VILLENEUVE LES BOULOC - FRANCE  
TÉL. +33 5 34 45 09 09 - FAX. +33 5 61 22 85 84

VIMS-SYSTEM.COM